

# Development of a necropsy protocol for newborn mice



Sara Capas-Peneda <sup>1,2\*</sup>, Gabriela Morello <sup>1,2</sup>, Colin Gilbert <sup>3</sup> & Anna Olsson <sup>1,2</sup>

<sup>1</sup> Laboratory Animal Science, IBMC – Instituto de Biologia Molecular e Celular, Universidade do Porto, Porto, Portugal | <sup>2</sup> i3S - Instituto de Investigação e Inovação em Saúde, Universidade do Porto, Porto, Portugal | <sup>3</sup> Babraham Institute, Cambridge, United Kingdom

\*sara.capas@ibmc.up.pt

## BACKGROUND & AIM

Laboratory mice pup mortality is a major welfare problem in animal facilities around the world and the mortality rates are reported as being, on average, 30%, specially in C57BL/6 mice. Furthermore, studying pup mortality is challenging, as dead pups are often eaten by the older mice before being found. As a result, the literature lacks specific guidelines for the appropriate necropsy of newborn cadavers. Therefore, we designed a necropsy protocol to inspect newborn mice for major malformations, presence of lesions in any of the major organs, as well as viability indicators, including presence of milk in the stomach and proof of breathing after birth.

## ANIMALS

### Housing

Breeding pairs and trios were maintained under SPF conditions in conventional static cages (Pairs: 1264C Type II ©, Tecniplast, Italy, 268 x 215 x 141 mm; Trios: 1290D Type III ©, Tecniplast, Italy, 425 x 276 x 153 mm) with food and water *ad libitum*. The room temperature was maintained between 20-24°C and relative humidity between 45-55% with a 12:12 light/dark photoperiod.

### Pup counting protocol and animals

Cages were inspected daily between 10h and 12h for the presence of pups and all pups were counted until four days postpartum. Newborn mice (n=135) originating from C57BL/6J breeding trios (n=70) and pairs (n=65) were found dead and collected. Dead pups had an average weight of 1.22 ± 0.19 g, aged 0.57 ± 0.81 days, and were 2.60 ± 0.21cm long.

## NECROPSY PROTOCOL

### EXTERNAL INSPECTION

- General condition
- Weight and crown to rump length
- Limbs
- Skin integrity
- Natural orifices (nostrils, mouth and anus),
- Eyes and head
- Hard palate
- Sex (anogenital pigmentation)

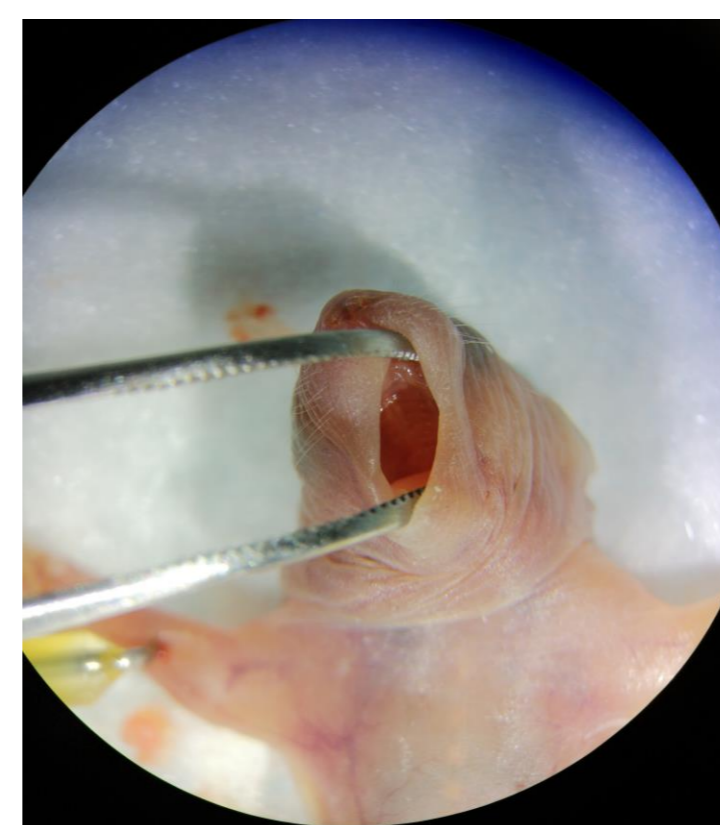


Fig. 1 – Inspection of hard palate

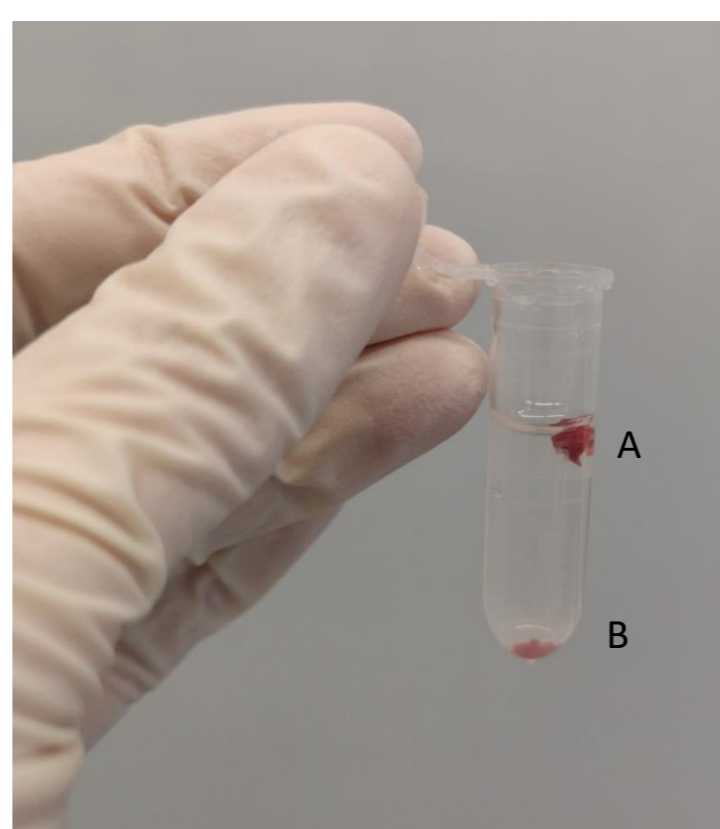


Fig. 2 – Lung floating test. A – Lung fragment; B – Liver fragment (control for decomposition)

### INTERNAL INSPECTION

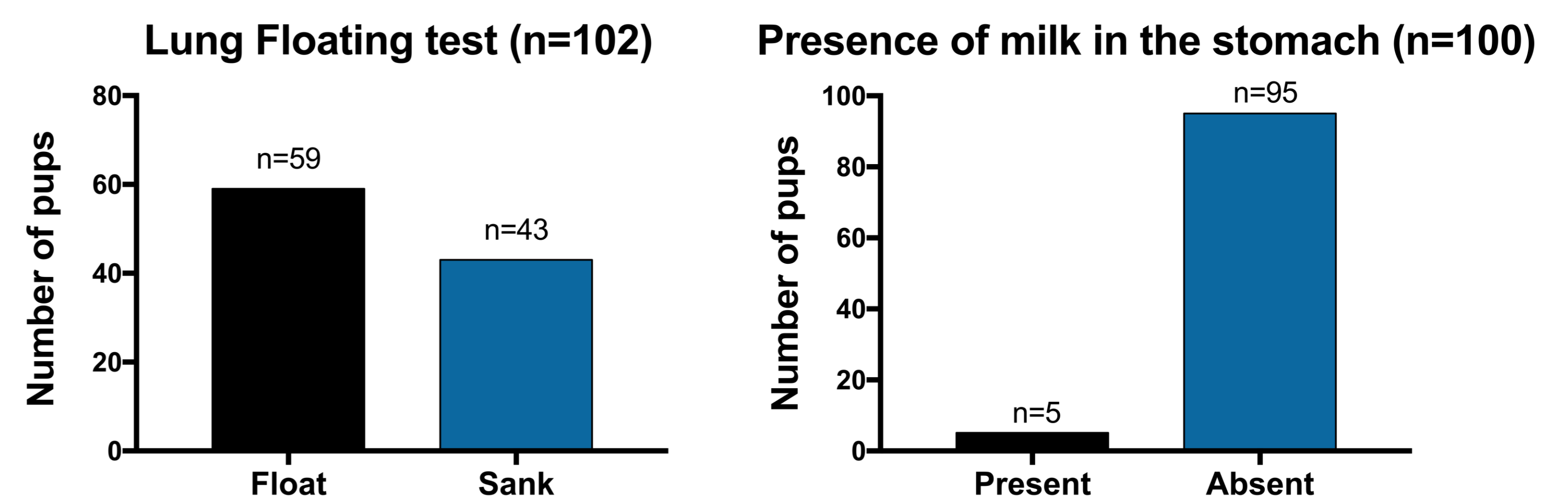
- Opening of the abdominal and thoracic cavities
- Visual inspection of all major organs,
- Stomach contents (inspection and contents characterization)
- Lung floating test (proof of breathing after birth)

## REFERENCES

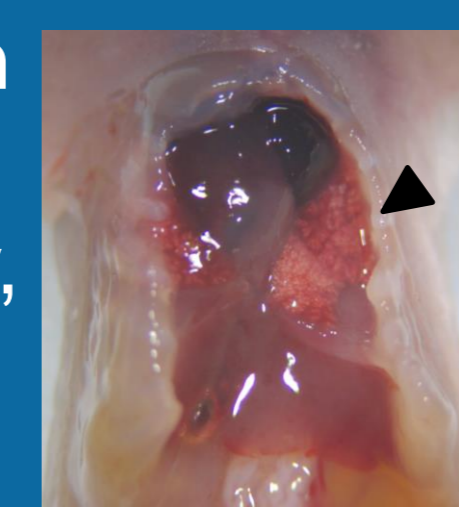
1. Weber, E.M., A.S. Olsson, and B. Algers, *High mortality rates among newborn laboratory mice - is it natural and which are the causes?*, in *Perinatal Death in Domestic Animals : The 20th Symposium of the Nordic Committee for Veterinary Scientific Cooperation (NKVet)*. 2007, Acta Veterinaria Scandinavica: Reykjavik, Iceland.
2. Mazuchowski, E.L., et al., *The Virtual Hydrostatic Test*. *Am J Med Pathol*, 2017. **38**: p. 24-28.
3. Ostendorf, A.-L.G., et al., *Is the lung floating test a valuable tool or obsolete? A prospective autopsy study*. *Int J Legal Med*, 2013. **127**: p. 447-451.
4. Brajon, S., et al., *Social environment as a cause of litter loss in laboratory mouse: A behavioural study*. *Applied Animal Behaviour Science*, 2019.

## RESULTS

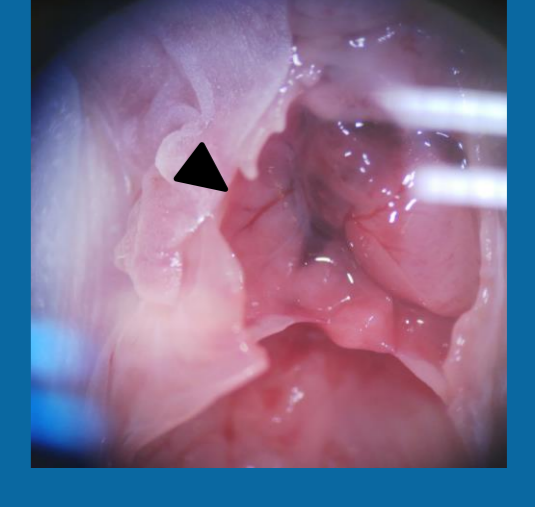
Dead pups had an average weight of 1.22 ± 0.19 g, aged 0.57 ± 0.81 days, and were 2.60 ± 0.21cm long.



- Only 7% of the pups had milk in their stomachs
- Macroscopically, air bubbles could be observed



- None of the pups which were found intact (86%) had milk in their stomachs
- Lungs were pale and smaller



### Postmortem findings

- Presence of air in stomach
- 33% of all pups presented some kind of traumatic lesion
  - Hematomas
  - Bite wounds
  - Some pups were partially eaten

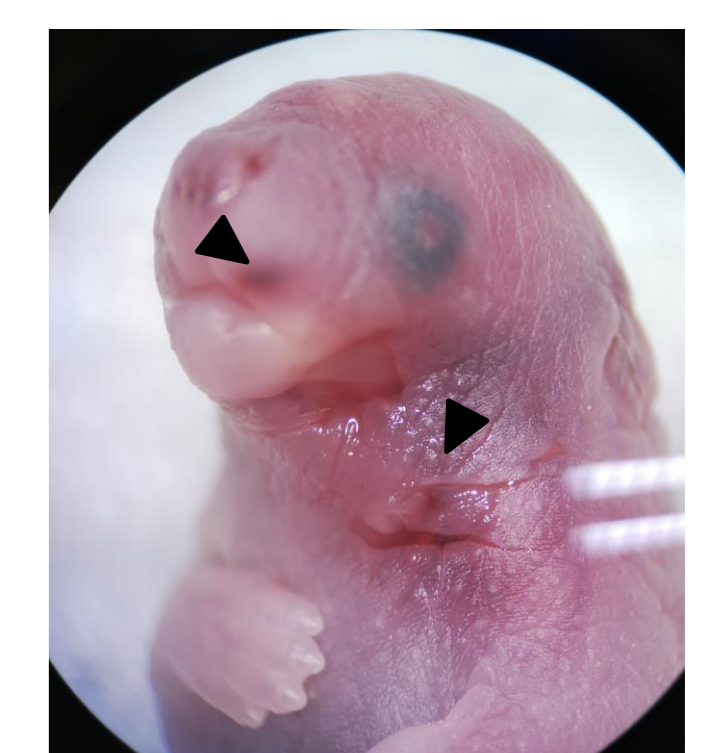


Fig. 4 – Hematoma and bite wounds

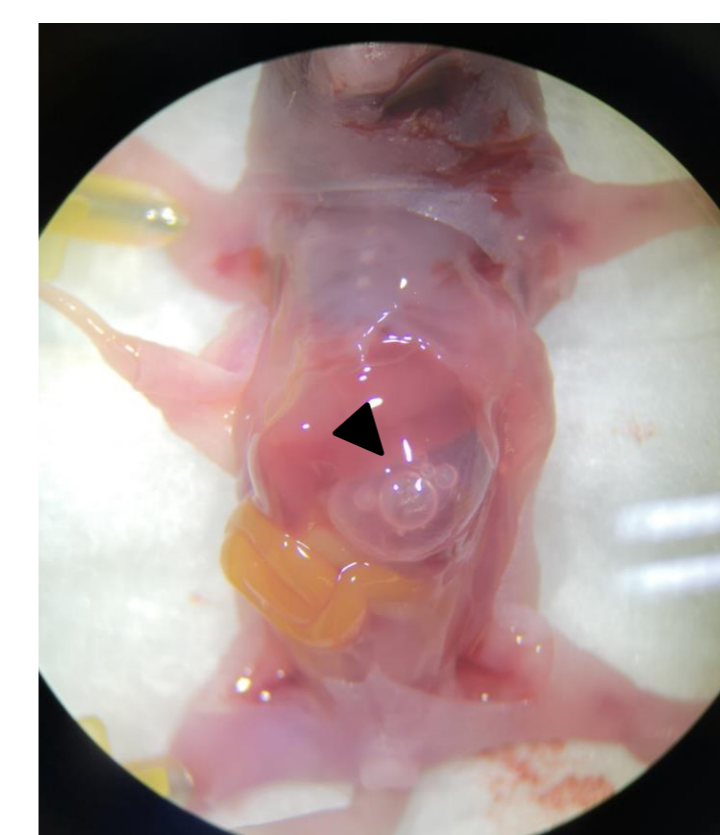


Fig. 5 – Presence of air bubbles in stomach

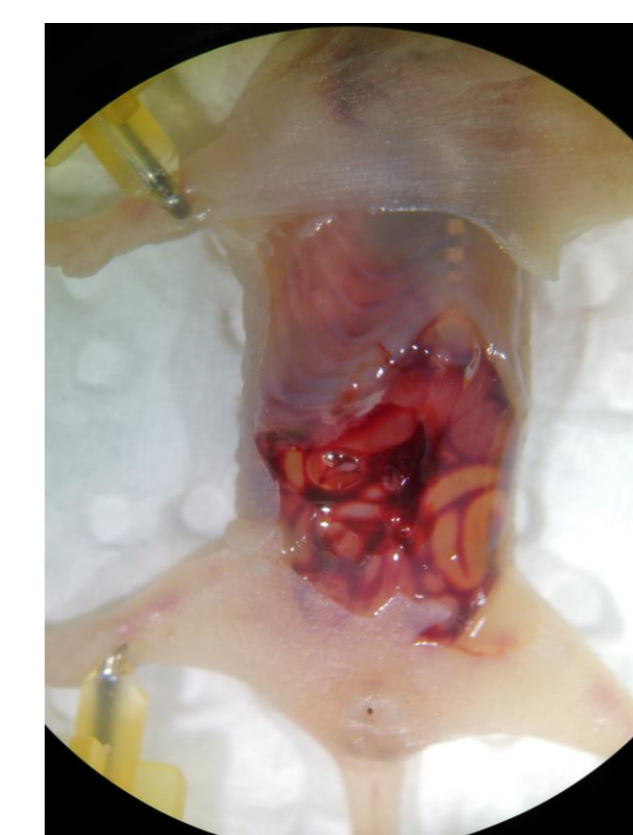

Fig. 6 – Internal bleeding

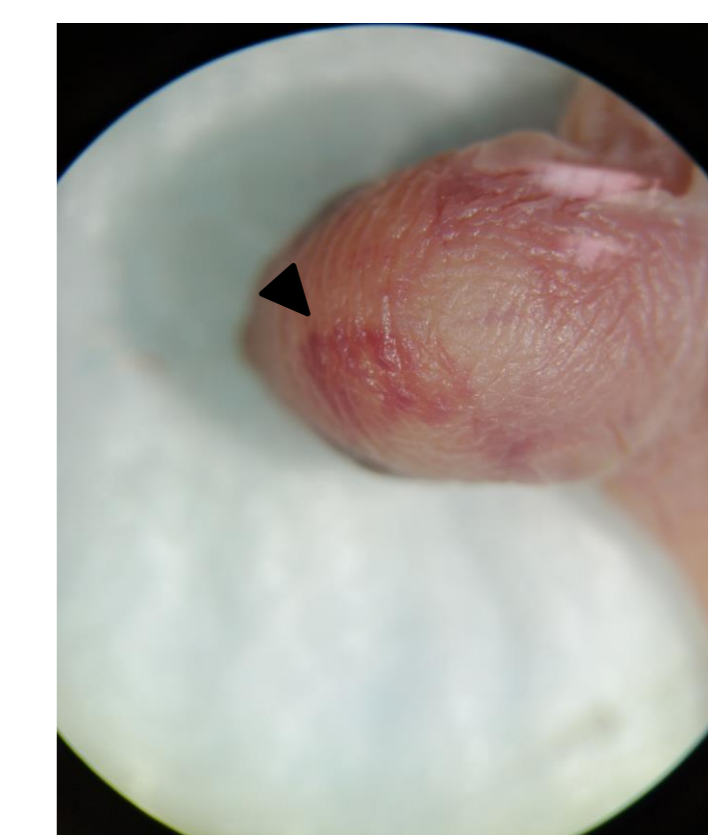


Fig. 7 – Head hematoma

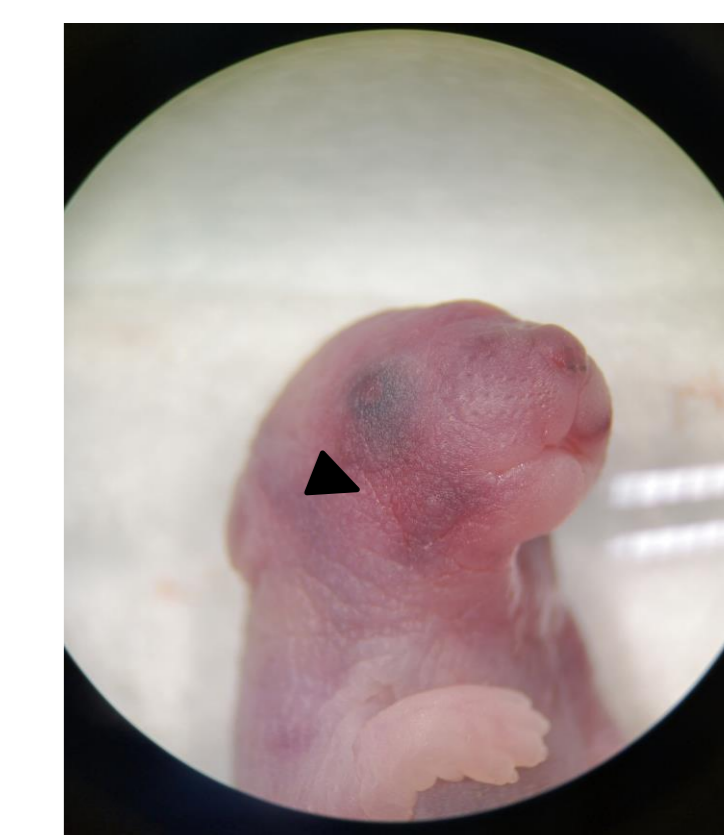


Fig. 8 – Face and head hematoma

## CONCLUSIONS & FUTURE PERSPECTIVES

- Lung floating test combined with macroscopic evaluation of lungs could be useful in determining if breathing occurred after birth
- Microscopic analysis of lung tissue will help validate the lung floating test
- Evaluation of stomach contents can help determine if a pup had access to milk after birth
- Results suggest that it is possible to determine if pups breathed and ate before dying, which is a starting point to further augment newborn post-mortem analysis.

## ACKNOWLEDGEMENTS

We would like to thank i3S Animal Facility and animal caretakers for their collaboration

### Funding sources:

This work was financed by FEDER – Fundo Europeu de Desenvolvimento Regional funds through the COMPETE 2020 – Operacional Programme for Competitiveness and Internationalisation (POCI), Portugal 2020, and by Portuguese funds through FCT – Fundação para a Ciência e Tecnologia/Ministério da Ciência, Tecnologia e Ensino Superior in the Framework of the Project PTDC/CVT-WEL/1202/2014 (POCI-01-0145-FEDER-016591)

